

Shelley Down
Recipient of BEVA Trust Travel Scholarship in 2009

Introduction

I attended the AO course on basic principles of fracture management in horses held in Oberdorf, Switzerland, from the 11-14th February 2009. This was a fantastic opportunity to be taught by some of the leading experts in equine fracture management, revise old and learn new techniques. This was also a great opportunity to pick up important tips from experienced surgeons, practice skills on 'dummy' limbs and as they said in the introduction, have fun!

Purpose of the visit

I attended this course to do what it says on 'the tin', to learn the basics of equine fracture management. There were several aims to attending the course. I wished to gain knowledge to help with future case management and improve the teaching of interns, visiting colleagues and students. This would also enable me to have a broader knowledge base for continual professional development (CPD) seminars at my place of employment and enable better guidance of referring veterinary surgeons requiring advice. Last but not least, the excellent teaching received would help me achieve successful passing of the RCVS examination in equine orthopaedic surgery.

Itinerary

Day 1:

On the first day we were picked up and taken to the Oberdorf Synthes centre. There had been a heavy fall of snow overnight, but the Swiss town continued as normal. Everyone was in good spirits and excited about the course ahead of us.

On arrival we were impressed with the display of human internal and external fixator devices. Various delegates identified equipment they had personally been treated with! (Fig. 1) At the start of the lectures I positioned myself between a previous University teacher, an old housemate and my previous co-intern.

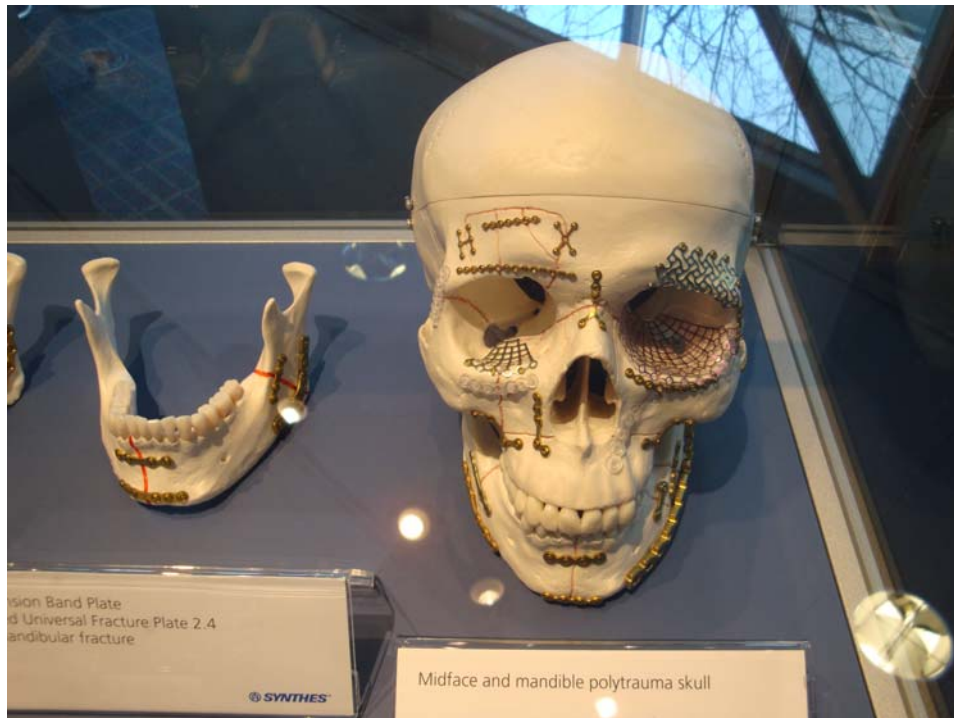


Fig. 1 Just one of the cabinets displaying human internal fixator devices at the Synthes centre in Oberdorf.

We were welcomed by Dr. Anthony Fürst, who was pleased that the course, now moved to Oberdorf, was still attracting attendees from around the world, despite the lack of local skiing. He advised us that we had participants as far a field as Australia. I noted that there was a variety of experience, including residents, clinicians and University lecturers. The speakers were introduced to us and included Dr. Fürst himself, Prof. Auer, Prof. Christoph Lischer, Dr. Patricia Hogan, Dr. Larry Galuppo, Dr. Brigitte von Rechenberg and Dr. Regula Bettschart.

Prof. Auer then took stage to explain the AO/ASIF foundation history and principals on which it was built. In a humorous introduction, he eloquently highlighted things that we associate with Switzerland and how that related to the AO/ASIF foundation: banks, watches, chocolate, skiing and the Swiss army knife. In the 1950's skiing became more accessible to the public. With the skiing came the fractures..... The fractures needed fixing (Swiss army knife = surgery?!), so along came the AO/ASIF foundation. The plates initially used would corrode, so with the use of a watchmaking company, other materials such as stainless steel were employed. This of course costed money (the banks). I can't remember where the chocolate came in now! We were taught the AO/ASIF foundation's philosophy, "Life is movement –movement is life", and that the 4 basic principles that the foundation developed were anatomic reduction, stable internal fixation, preservation of blood supply and early, active, pain free mobilisation.

Prior to the course we had all been sent notes on AO/ASIF principals, equipment, bone healing and biomechanics and warned to come prepared. When we were each handed individual test sheets a few delegates turned pale, although answers were undertaken as a group. I was interested to hear that even following fracture remodeling, histologically a fracture line is still evident in almost all cases. I was also interested to learn that horses have very slow bone metabolism. At least 3 months are required for fracture 'healing' and it takes approximately 1 year before bone has the same strength as before fracture.

We were then given lectures on the function and application of screws (Prof. Auer), and related these principles to a clinical example (Diagnosis and management of simple sagittal fractures of the proximal phalanx, Prof. Lischer). Key points included, the difference between a lag screw and placing a screw in 'lag fashion', obtaining good images, presurgical preparation (stabilising the patient first, pre-surgical planning of screws/plates), using anatomical landmarks and post operative management such as placement of a half limb cast for recovery. We were all taught a new song to ensure we would remember the order to undertake things. This was to the tune of 'row, row, row your boat gently down the stream', of which we will all now sing, 'drill, drill, countersink, measure, tap and screw!'

Dr. Hogan then gave an informative lecture on the repair of lateral condylar fractures of the third metacarpal/metatarsal bones. As a veterinarian in private practice, without the help of interns and fluoroscopy, she gave practical tips throughout. Advice was given for common mistakes and tips to fix intra-operative complications. Take home points were to take oblique radiographic views as fracture lines may take a palmar/plantar path, screw as close to the articular margin as possible to gain maximum compression, don't drill perpendicular to the floor (use a guide such as a k-pin) and use arthroscopy to give an accurate prognosis and assess the amount of compression achieved.

The first two practical sessions involved putting theory into practice! First we learnt how to use the screws and place them in lag fashion and neutral position (Fig. 2). Next we undertook a lateral condylar and simple first phalangeal fracture. For all practical sessions, work was done in pairs. Multiple large television screens were hung from the ceiling allowing delegates to watch demonstrations showing landmarks and technique. Speakers were on hand to advise and give guidance or advise us of mistakes that people were making along the way.



Fig. 2 Getting to grips with the equipment (ideally watch what you are doing!)



Fig. 3 Lateral condylar and simple proximal phalangeal fractures requiring fixation (note the presence of a lateral collateral ligament in the dummy model).

Following lunch, we were hard at work again learning about stress fractures of the third metacarpus (Dr. Galuppo), and indications and applications of casts and transfixation casts (Prof. Lischer). An important point when transfixation casting was to place pins at 30 degrees to each other to decrease pin stress and breakage; keep the distance between the bone and the cast as little as possible (again to reduce pin breakage) and use central positive profile pins only (not self tapping and self drilling). The multiple complications of transfixation casts were discussed at length with examples, and ways to minimise such complications were given.

Prof. Auer then guided us through diagnosis and management of some selected mandible and maxillary fractures in the horse. We were taught a differing technique for fracture fixation of the incisor teeth to cerclage wire fixation that we may have been previously used to. Interestingly this method had come via the AO/ASIF illustrator! The illustrator had been asked to draw diagrams for the veterinary manuals/courses as well as for the human. He had wondered why we used such a differing method, and showed the veterinary team the technique used in humans. This technique (Obwegeser technique) was then tried and tested, and has been used ever since. It just goes to highlight what integration of human and veterinary medicine can often achieve. Use of pin-less fixators (originally developed for motorbike accident patients where fractures required stabilisation, but internal fixation methods could not be used due to marked initial loss of soft tissue), screws, plates and external fixation devices was then discussed.

Dr. Hogan then discussed diagnosis and operative management of slab fractures of the third carpal bone, using examples from cases within her clinic. She warned us to 'beware the chronic or short incomplete fracture' (that may only result in mild lameness), and that intra-articular analgesia may be very short lived (5 minutes) in some cases. She also advised that the carpometacarpal joint be defined prior to joint inflation for arthroscopy, otherwise disorientation may occur.

The importance of first aid and transport of the fracture patient was undertaken by Dr. Fürst. Examination, first-line treatment and stabilisation were all discussed in detail with examples to highlight important points. Dr. Hogan finished up the day by talking on diagnosis and management of proximal sesamoid fractures. She highlighted the need for use of arthroscopy to debride any fragmentation and guide fracture reduction using bone reduction forceps. She also highlighted that due to fibrous type union of these fractures, a long recovery time was required. Ideally 2 screws would be placed where possible in order to reduce rotation around a single screw.

Weary from a long day of learning and practicals, we all headed back to our respective hotels (and some to their casebooks...), ready for a good nights sleep for another day of excellent teaching.

Day 2

On the second day we started bright and early in a practical class undertaking lag screw fixation of a third carpal bone slab fracture (Fig. 4) and lag screw fixation and osteostixis of a third metacarpal bone stress fracture. Now, used to the equipment, most delegates

were very proficient at these procedures; it seemed that these poor 'horses' had had multiple stress fractures of the third metacarpal bones as delegates were ensuring maximum practice on each limb!

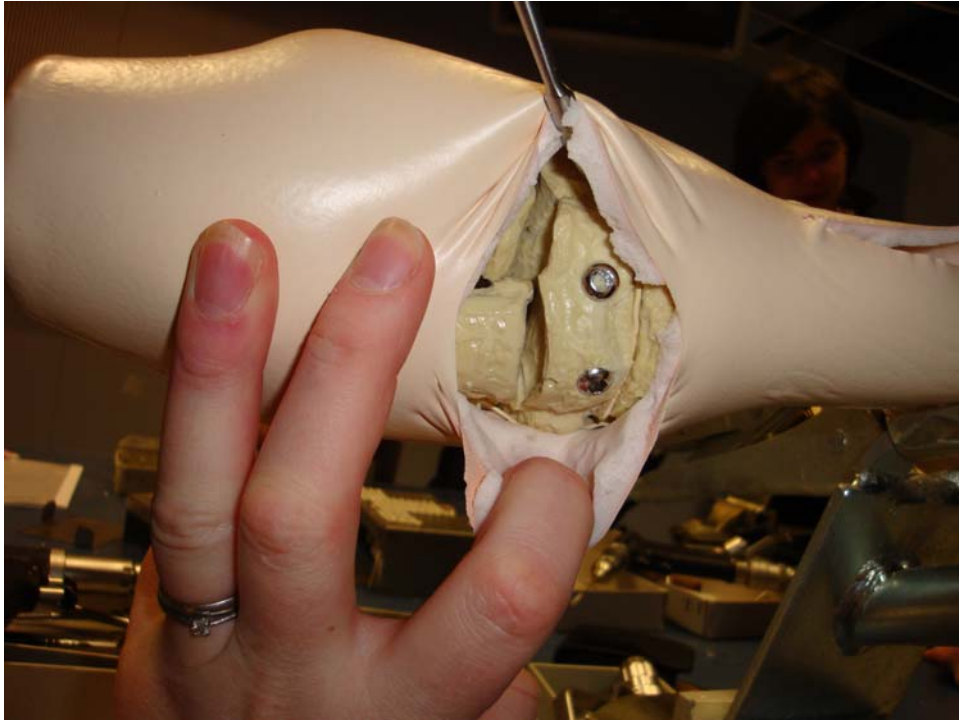


Fig. 4 Lag screw fixation of a third carpal bone slab fracture.

The first lecture of the day (Prof. Auer) explained plate application and function. Dr. Gallupo then advised us how to diagnose and repair simple olecranon fractures. Key points included taking multiple radiographic views, especially if the degree of lameness did not correlate with the fracture configuration, adequate pre-surgical planning and pre-surgical stabilisation (fix the knee!), use of a curved incision to prevent break-down at the point of the elbow and use of assisted recovery.

The second practical of the day involved wiring of the incisor teeth (using the Obwegeser technique, Fig. 5), and application of the pinless fixator to a mandibular fracture. All delegates who had not use the Obwegeser technique before were impressed with the ease of the technique and the stability gained. Simple tips such as twisting the wire placed between the second premolar tooth and the incisors to create greater tension was also employed.

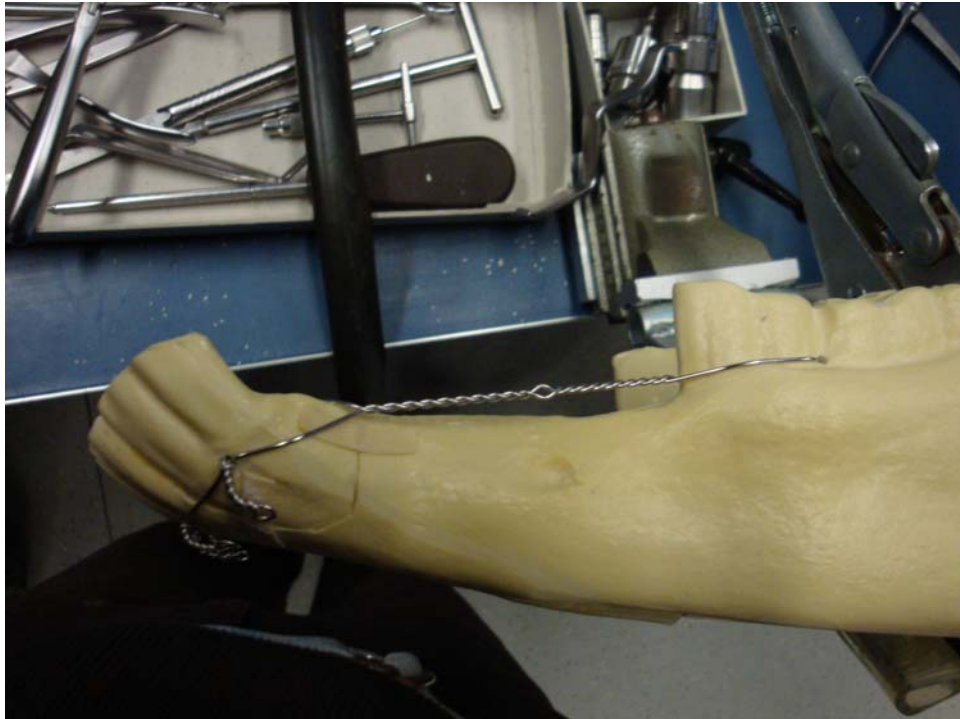


Fig. 5 Application of the Obwegeser technique for stabilisation of a fracture of the corner incisors of the mandible.

Following another delicious lunch, a lecture was given on the indications and operative techniques for proximal interphalangeal joint arthrodesis (Prof. Lischer). Key points included the use of 5.5 cortical screws for all positions (3 hole dynamic compression plate [DCP] and 2 lag screws) apart from the most proximal hole in the DCP plate in order to decrease instability and therefore quicken joint fusion and decrease risk of infection; and ensuring that the 2 lag screws incorporated the palmar aspect of the joint to provide palmar compression (the DCP plate would provide compression dorsally). Treatment of angular limb deformities using periosteal stripping and growth retardation techniques (Dr. Hogan) was explained next. We were warned that any transphyseal bridging should be monitored closely to allow correct timing of removal. A good tip when undertaking transphyseal bridging using the screw and wire technique was to pre-bend the wire in order to hook over the screw head and prevent the wire from slipping off the screw head post surgery.

The second practical of the day started with growth retardation techniques. First we undertook tension band wiring of the distal radius, followed by a single position screw technique across the distal third metacarpal bone physis. Following this we undertook plate repair of a simple olecranon fracture. We were told that this was a competition. It's amazing how silent a room can go when there are prizes at stake! I have to say that my partner and I did a great job, but unfortunately we were not in the money.

Following more strong coffee and cakes, it was time for the delegates to show previous handiwork. Cases were presented of various fracture configurations, differing methods of fixation and problems encountered. Delegates asked questions to the panel, and healthy discussions between members of the panel ensued! A great amount of practical tips were given to resolve problems that we may encounter and how to prevent them.

That evening we were taken to a local farm in Bubendorf for the course dinner. Prizes were handed out to the best 3 olecranon fracture repairs. We then had a presentation given to us about the host's family farm and its history. The farm had been in the family for several generations, and had become a place for gatherings such as weddings. They had cherry trees on the farm from which they made Kirsch as well as cattle and goats. Recently they had built an entertaining area in one of the barns to supply the demand for a place for parties and gatherings. Around the walls of the building were pictures of the traditional walk the farmers, goats and cattle made from the mountains to return to the village for the winter. This was always done in a particular manner with the farmers leading the goats followed by the cows. The cows all wore specific bells around their necks - some large and some small, all which made a different chime. Examples of all the different types of bells were hung outside the barn (Fig. 6). Our host then proceeded to give us a demonstration of the sound that is created when the animals process into the village from the mountains, by ringing all the bells! Before dinner we were also invited to go and see the cattle and goats in the shed, which was of interest to us all (Fig. 7). A delicious traditional Swiss dinner was served and we all had a good night.



Fig. 6 A few of the cow bells outside the barn where the course dinner was held.



Fig. 7 “Horse vets in a cow shed”. From left to right: myself, Jenny Griffiths and Anna-Maria Nagy with other delegates in the cattle shed at the course dinner!

Day 3

The day started with lectures on bone grafting in the horse (Prof. Lischer), followed by diagnosis and management of fractures of the small metacarpal /metatarsal bones (Dr. Fürst). We were then given a very informative lecture on anesthetic management of the equine orthopaedic trauma patient (Dr. Bettschart-Wolfensberger). We were advised of the marked importance of pre-surgical stabilisation of fracture patients prior to anaesthesia. Ideally horses should be given time to adjust to their current condition, calm down and given fluids, pain relief, and treatment for shock as appropriate. This greatly reduces anaesthetic complications.

We learnt of the medetomidine-isoflourane protocol used at the University of Zurich for the majority of such patients. This involves premedication with acepromazine maleate (providing there was adequate packed cell volume), to decrease risk of fatality, provide sedation without ataxia, improve peripheral perfusion and improve recovery. Horses are then generally given pain relief with non-steroidal anti-inflammatory drugs plus the use of opioids (morphine, intramuscular or epidural) if required. A short acting α_2 -agonist (medetomidine) is given pre-surgery (so that side effects are also short acting), given by the intravenous route, slowly to effect (to avoid over-dosing). Anaesthesia induction is undertaken with intravenous ketamine and diazepam. Anaesthesia is maintained using isoflourane and a constant rate intravenous infusion of medetomidine. The horse is given intramuscular morphine 30 minutes prior to the end of anaesthesia and intravenous medetomidine 10 minutes after cessation of anaesthesia to aid an improved recovery.

Medetomidine causes sedation as well as potent analgesia; half life is short and elimination is rapid; its kinetics favour constant rate infusion. Studies using the medetomidine-isoflourane combination have shown to reduce the maintenance need of isoflourane, reduce the requirement for dobutamine, cause less variable heart rates and intra-arterial blood pressure measurements and increase lateral recumbency time during the recovery period than lidocaine-isoflourane combination. We were warned that if medetomidine was used, horses should look 'lighter' than anesthesia with isoflourane only, and that a urinary catheter should be placed due to increased urine production.

Dr. Fürst then gave a lecture on the use of antibiotics in equine fracture patients before the final practical of the course. This involved arthrodesis of the proximal interphalangeal joint using a 3-hole 4.5 DCP plate and lag screw technique (Fig. 8), and repair of a proximal fourth metacarpal bone fracture. The difference in the usage of instruments over the 3 days was obvious to all, with all delegates now competent in the use of the equipment. The arthrodesis technique really brought together all skills learnt and was great fun to undertake. Metacarpophalangeal bone fracture repair revealed to us the delicate nature of repairing such small bones in the horse.

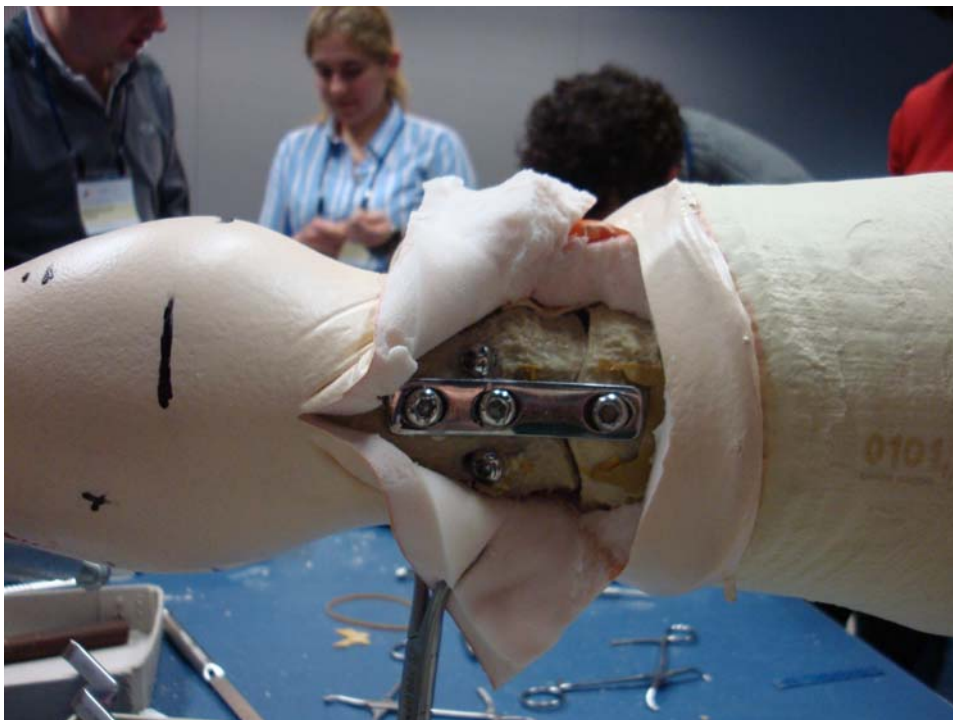

Fig. 8 Proximal interphalangeal joint arthrodesis using a 3-hole Dynamic Compression Plate and 2 screws placed in lag fashion.

Following a final lunch, lectures on postoperative care of the fracture patient (Dr. Galuppo), technical errors (Prof. Auer), implant removal (Prof. Aeur) and recognition of infection in patients treated with orthopaedic implants (Dr. Galuppo) were given. We were interested to learn of the multiple forms of assisted recovery, including use of a sling at Davis University and pool recovery at The University of Zurich. Videos were

shown to highlight both. It was comforting to see technical errors that had been made by accomplished surgeons (and remember that we improve by learning from our mistakes) and how to deal with such situations (and to avoid them!). I was also interested to hear that Dr. Galuppo swabbed the surgical plate prior to closure for bacterial culture and sensitivity. Should there be infection at the surgical site, then he was ready with the appropriate antimicrobial protocol and therefore aiming to stay one step ahead all the time. Dr. Fürst then closed the course and thanked all the faculty and relevant helpers of the course and congratulated the delegates on being a great group (what can I say...). Certificates were collected and we all headed back to our hotels safe in the knowledge that we had learnt a great deal, made new friends and definitely had fun.

Conclusion

This course provided excellent teaching, covering all aspects of basic principals of fracture management including principals of bone healing and pre-, intra- and post-surgical management of the fracture patient. The practical sessions allowed delegates to put into practice the principals learnt, and allowed delegates to learn how to use the equipment appropriately under expert guidance. The AO/ASIF principals and aims were outlined and followed. The facilities were excellent and we were all fed extremely well! I would highly recommend this course to anyone who wishes to undertake internal fixation techniques in the horse. I am very grateful to the BEVA Trust for supporting my participation in the course.